



ISBN 1478-6672

HEMORRHAGIC CYSTIC ACOUSTIC NEUROMA PRESENTING WITH ACUTE FACIAL AND ABDUCENT NERVE PALSY

Sarsam Z, MD ¹, Mussad R, MD ¹, Rainov NG, MD DSc FRCSEd ^{2, 3}

¹ Department of Neurosurgery, The Walton Centre for Neurology and Neurosurgery NHS Trust, Liverpool L9 7LJ, United Kingdom, ² Department of Neurosurgery, Klinikum Augsburg, D-86156 Augsburg, Germany; ³ Department of Neurosurgery, Martin-Luther-University Halle-Wittenberg, D-06097 Halle, Germany

ABSTRACT

This 68-years old Caucasian male presented with sudden acute onset of occipital headache and double vision. Neurological exam diagnosed right-sided facial and abducent nerve palsy. The attack was preceded by mild unsteadiness and sensorineural hearing loss of two months duration. CT and MRI demonstrated a large cerebellopontine angle cyst with fluid level and intracavitary blood. The cyst was excised and histological examination revealed acoustic neuroma.

This is a rare case of isolated hemorrhage into a cystic acoustic neuroma with atypical acute presentation and ipsilateral facial and abducent nerve palsy on the background of hearing loss of short duration. Differential diagnosis of acute facial and abducent nerve palsy may have to include such lesions.

Keywords: acoustic neuroma • cyst • intratumoral hemorrhage

Objective and importance

Acoustic neuroma (AN) presenting as hemorrhage in a cystic structure is an uncommon entity. Hemorrhage with AN may take the form of a subarachnoid and/or intratumoral bleed and is likely to be related to the rate of growth and tumor vascularity [1, 4, 6]. It is extremely rare for AN to present as a thin-walled non-enhancing cyst which contains fluid and demonstrates fresh blood forming a level within the cyst.

Clinical Presentation

This 68-years old Caucasian male presented with two months history of right sensorineural hearing loss and

mild unsteadiness. Sudden acute symptoms occurred one morning when he started complaining of severe occipital headache, right facial numbness, and double vision. The only past medical history of note was treated arterial hypertension. Neurological examination revealed a fully alert and oriented patient with right facial nerve palsy (House-Brackman Grade III) and right abducent nerve palsy.

CT scan performed immediately after admission demonstrated a right cerebellopontine angle (CPA) cyst with an intracystic hyperdense structure and a fluid-blood level (Fig. 1 A). Subsequently, T1-weighted MRI confirmed an extra-axial cyst indenting the cerebellum and right side of pons. The cyst did not show uptake of gadolinium, apart from some minor

enhancement within the internal acoustic meatus. Signal intensity was low, with some areas of bright signal suggestive of recent hemorrhage (Fig. 1 B). T2-weighted images demonstrated methemoglobin signals in the cyst and a fluid-blood level (Fig. 1 C). Cerebral angiography (DSA) was performed and a vascular malformation was excluded.

Based on the radiological findings and on lacking enlargement of the internal acoustic meatus, the differential diagnosis was that of acute intracystic hemorrhage in a lesion of unknown origin.

Intervention

The mass was approached through a right retrosigmoidal craniectomy with facial nerve monitoring. The cystic component was exposed and clear xanthochromic fluid evacuated along with an intracystic organised clot. Following cyst drainage, a small solid tumor mass extending through the meatus was identified, with the facial nerve wrapped around its medial aspect. The solid component was excised including the intra-canalicular part while the continuity of the facial nerve was maintained. However, no response was detected on intraoperative facial nerve stimulation at any point during the procedure. Histological examination of specimens revealed alternating Antoni A and Antoni B areas consistent with a WHO Grade 1 AN (Fig. 2 A-B). There were no postoperative com-

plications, however the facial nerve function did not improve over a follow-up period of 4 months.

Discussion and conclusions

We describe here a rare case of hemorrhage into a cystic AN with atypical acute presentation on the background of hearing loss of short duration. The patient presented with sudden onset of occipital headache suggestive of a vascular event. Moreover, there were acute facial and abducent nerve palsy on the side of the cyst, which were not viewed as typical signs of an AN. The tumor was mostly cystic and the only hint to the possibility of an AN was some gadolinium uptake within the internal acoustic meatus on MRI (Fig. 1 B).

Ro et al. (1995) reported an AN case with combined abducent and facial nerve dysfunction presenting as a false localizing sign. Their patient had trigeminal nerve dysfunction in addition to the abducent and facial nerve deficits, which were caused by a contralateral AN. The authors suggested that the unusual tumor characteristics and individual anatomic variations of the patient were the factors influencing the occurrence of contralateral focal neurological deficits [9]. In our case, the sixth and seventh nerve palsy was localized on the ipsilateral side of the AN. It was suspected that a preexisting non-symptomatic compression of these

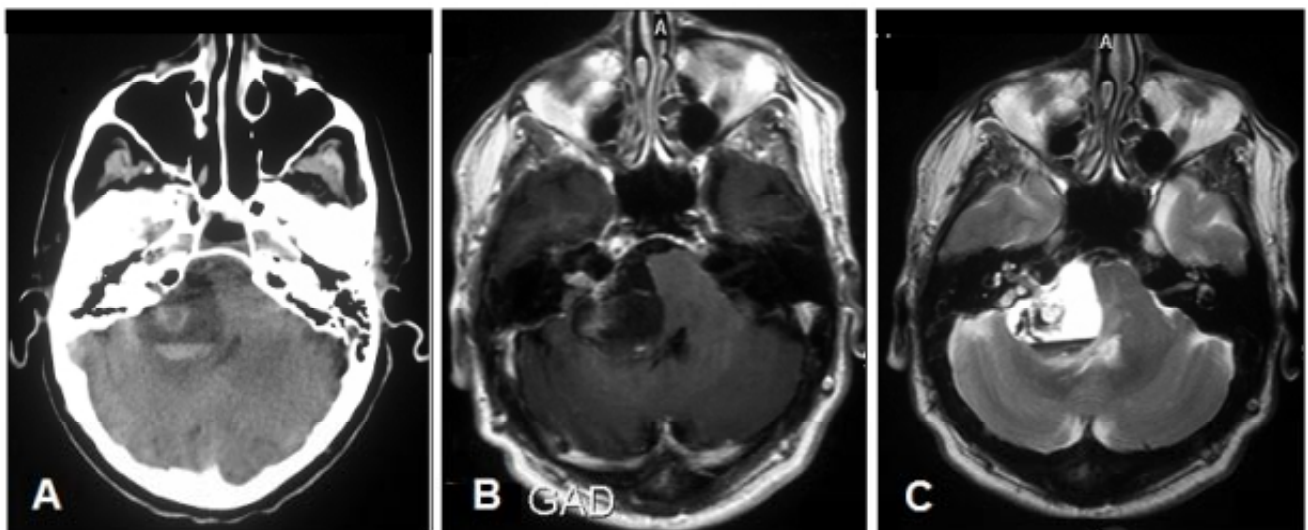


Figure 1: A: CT scan showing a low density lesion in the right CPA with a hyperdense intracystic component and fluid level. B: T1-weighted MRI scan with gadolinium enhancement showing some enhancement within the internal acoustic meatus. C: T2-weighted MRI scan demonstrating high signal in some areas of the cyst.

nerves by the relatively soft cystic tumor was exacerbated by the acute intratumoral hemorrhage causing increase of local pressure in the posterior fossa.

There are few literature reports of AN with single or multiple macroscopic cysts. Degenerative changes

intracanalicular AN [2]. Spontaneous intratumoral and/or subarachnoid macrohemorrhage related to AN has also been described previously [1, 8]. It was suggested that a large or rapidly growing tumor, mixed Antoni type and increased vascularity may be risk factors for hemorrhage in AN [3].

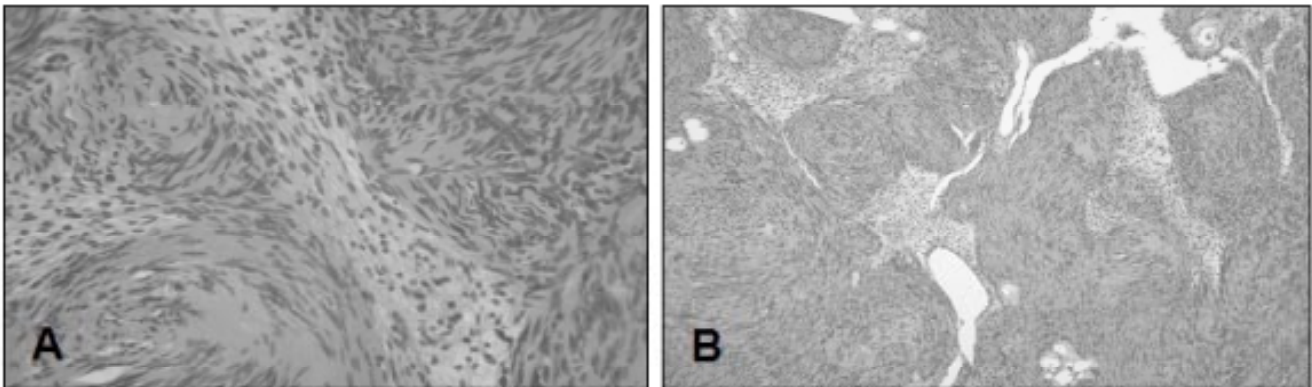


Figure 2: A and B: Histological sections showing Antoni A and Antoni B arrangements typical of acoustic neurinoma (H&E staining, original magnification A - x200, B - x120).

appear to be the principal cause of cyst formation and may occur in 5-13% of all AN [2, 5, 10]. Park et al. (2006) studied cystic and solid AN to determine the pathogenesis of the cystic subgroup [7]. Neuroimaging confirmed the presence of either fluid-fluid level or hemosiderin deposits in all cystic AN. Histological evidence of microhemorrhages and abnormal vessel proliferation was significantly more frequent in cystic AN compared with solid AN. The authors suggested that intratumoral microhemorrhage may be a possible mechanism of pathogenesis in cystic AN such as in our case. On the other hand, the large cystic component described in our case could also represent an arachnoid cyst collocated and formed around a small

The published literature contains reports of either cystic AN or hemorrhage associated with solid AN, but not of both. We could identify only one report bearing some similarity to our case, which described a large AN consisting of a solitary cyst with intracystic fluid level [8].

In conclusion, this report describes a rare case of hemorrhage within a cystic AN appearing on CT and MRI as a solitary cyst with fluid level. Although the presented case seems to be a rare occurrence, it should be nevertheless born in mind when investigating acute facial and/or abducent nerve palsy.

References

1. Asari S, Katayama S, Itoh T, Tsuchida S, Furuta T, Ohmoto T: Neurinomas presenting as spontaneous intratumoral hemorrhage. *Neurosurgery* 31: 406-411, 1992
2. Charabi S, Tos M, Thomsen J, Rygaard J, Fundova P, Charabi B: Cystic vestibular schwannoma - clinical and experimental studies. *Acta Otolaryngol Suppl* 543: 11-13, 2000
3. Kim SH, Youm JY, Song SH, Kim Y, Song KS: Vestibular schwannoma with repeated intratumoral hemorrhage. *Clin Neurol Neurosurg* 100: 68-74, 1998
4. Misra BK, Rout D, Bhiladvala DB, Radhakrishnan V: Spontaneous haemorrhage in acoustic neurinomas. *Br J Neurosurg* 9: 219-221, 1995
5. Muzumdar DP, Goel A, Pakhmode CK: Multicystic acoustic neurinoma: report of two cases. *J Clin Neurosci* 9: 453-455, 2002
6. Ohta S, Yokoyama T, Nishizawa S: Massive haemorrhage into acoustic neurinoma related to rapid growth of the tumour. *Br J Neurosurg* 12: 455-457, 1998
7. Park CK, Kim DC, Park SH, Kim JE, Paek SH, Kim DG, Jung HW: Microhemorrhage, a possible mechanism for cyst formation in vestibular schwannomas. *J Neurosurg* 105: 576-580, 2006
8. Patel PJ, Kolawole TM: Acoustic neuroma presenting as a cyst with fluid level. *J Comput Tomogr* 11: 383-384, 1987
9. Ro LS, Chen ST, Tang LM, Wei KC: Concurrent trigeminal, abducens, and facial nerve palsies presenting as false localizing signs: case report. *Neuro-*

surgery 37: 322-324, 1995

10. Tali ET, Yuh WT, Nguyen HD, Feng G, Koci TM, Jinkins JR, Robinson RA, Hasso AN: Cystic acoustic schwannomas: MR characteristics. Am J Neuroradiol 14: 1241-1247, 1993

Correspondence:

Nikolai G. Rainov, MD DSc FRCSEd, Department of Neurosurgery, Klinikum Augsburg, Stenglinstr. 2, D-86156 Augsburg, Germany; Tel. +49 821 400 2251; FAX +49 821 400 3314; Email: nikolai.rainov@medizin.uni-halle.de

Comment

Sarsam et al. have presented on “Hemorrhagic Cystic Acoustic Neuroma Presenting with Acute Facial and Abducent Nerve Palsy.” This tumor was operated on with an excellent result, and the pathology was consistent with a hemorrhagic acoustic neuroma. In my own experience, I have seen several cystic acoustic neuromas, but not one with an acute hemorrhage. In extrapolating the experience with cystic tumors, I feel that the dissection is somewhat easier since you can debulk the tumor rapidly, and then try and preserve the facial nerve. It would be interesting to see with radiosurgery being used for acoustic neuromas whether radiation can cause such an effect as well. This is an important entity that should create awareness among neurosurgeons, not only in acoustics but also in other tumors.

Anil Nanda, MD FACS
Shreveport

© 2006, Annals of Neurosurgery